

Elbow Trauma: Rehabilitative Evaluation and Treatment

IMAGES

IMAGE 1

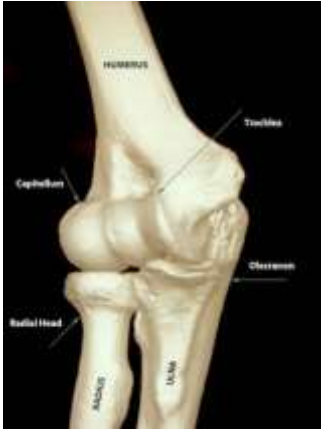

IMAGE 2

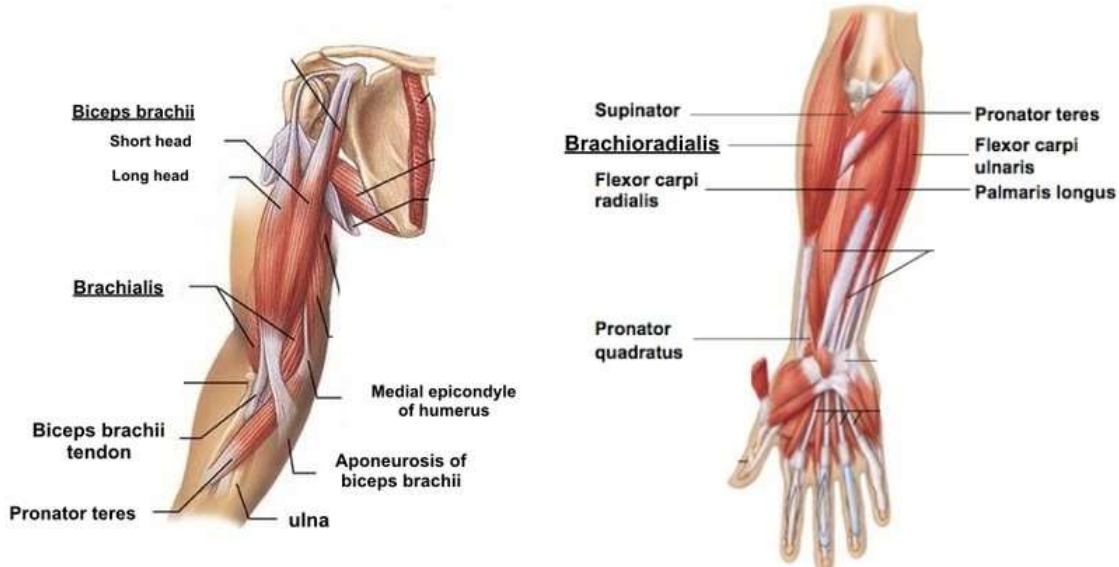


IMAGE 3

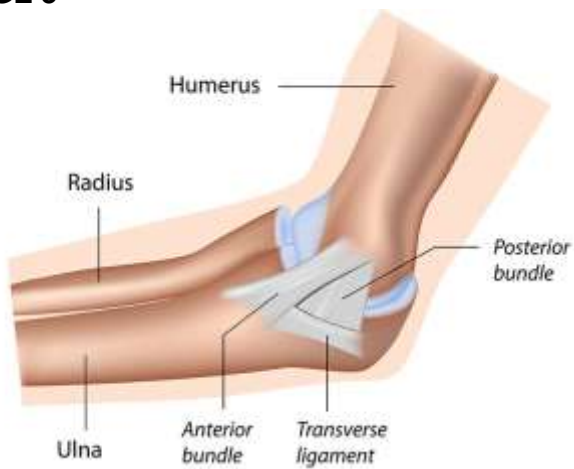

IMAGE 4

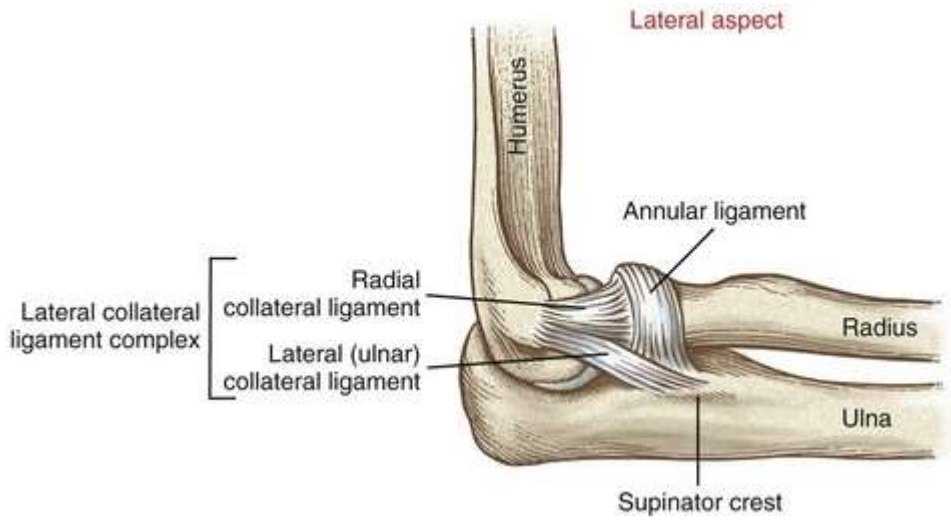


IMAGE 5

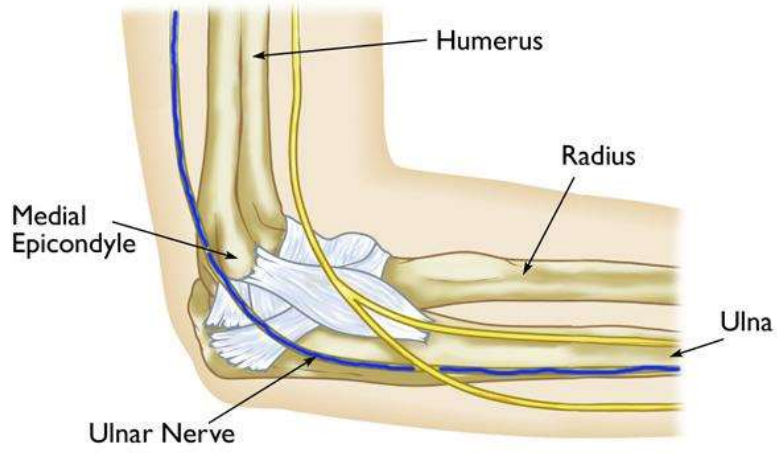


IMAGE 6

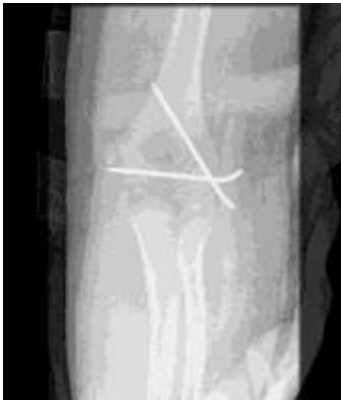

IMAGE 7

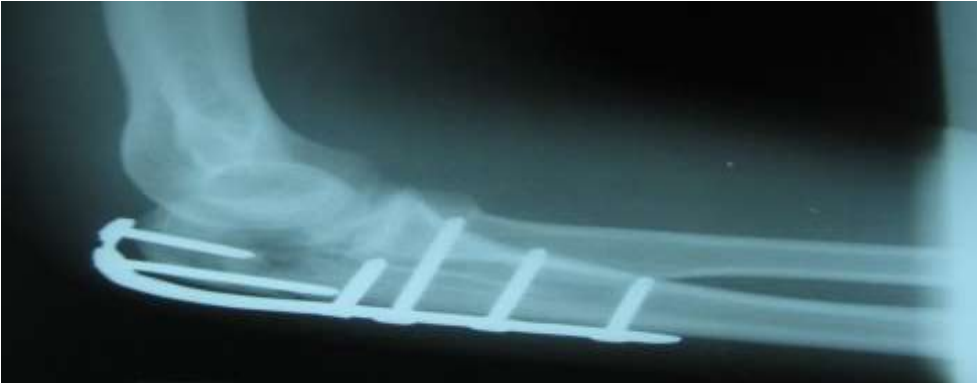

IMAGE 8

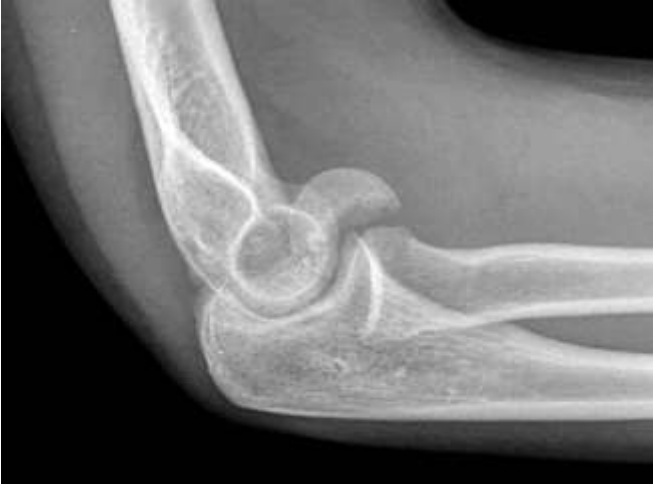

IMAGE 9

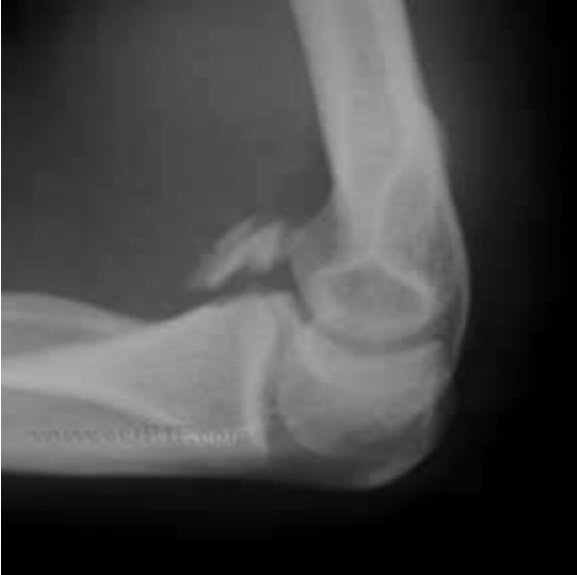

IMAGE 10

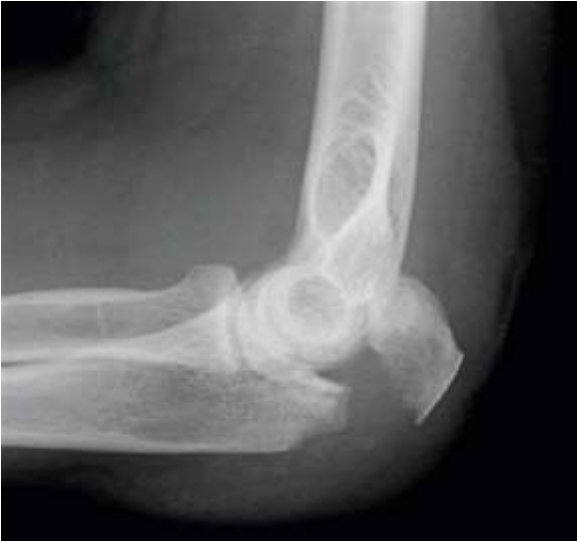

IMAGE 11

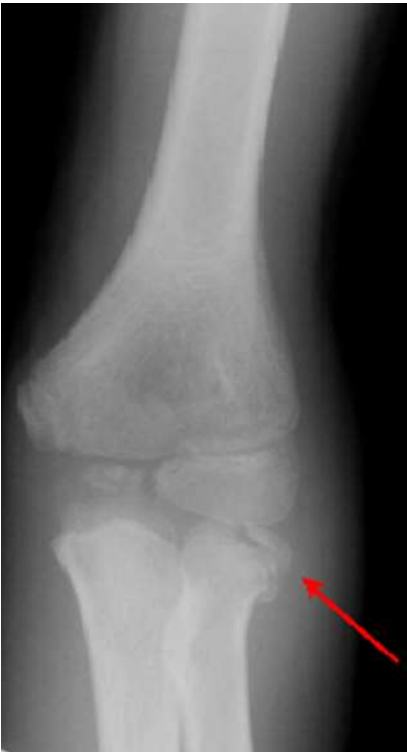

IMAGE 12

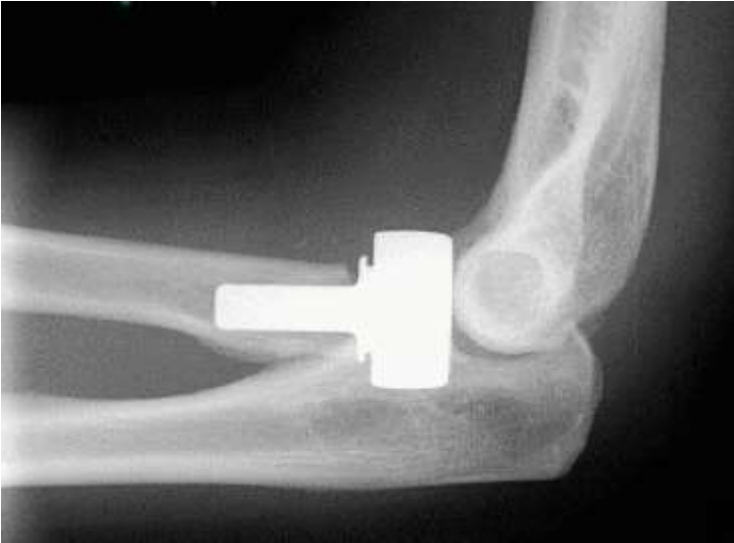

IMAGE 13

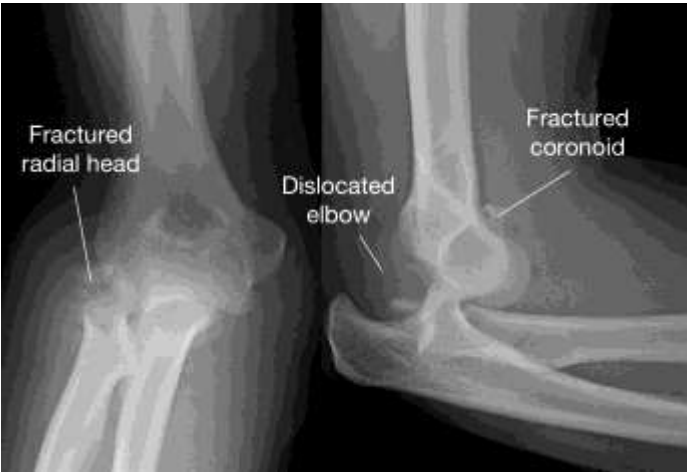


IMAGE 14

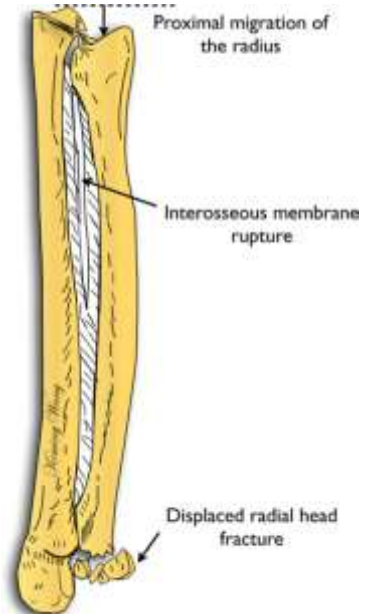


IMAGE 15

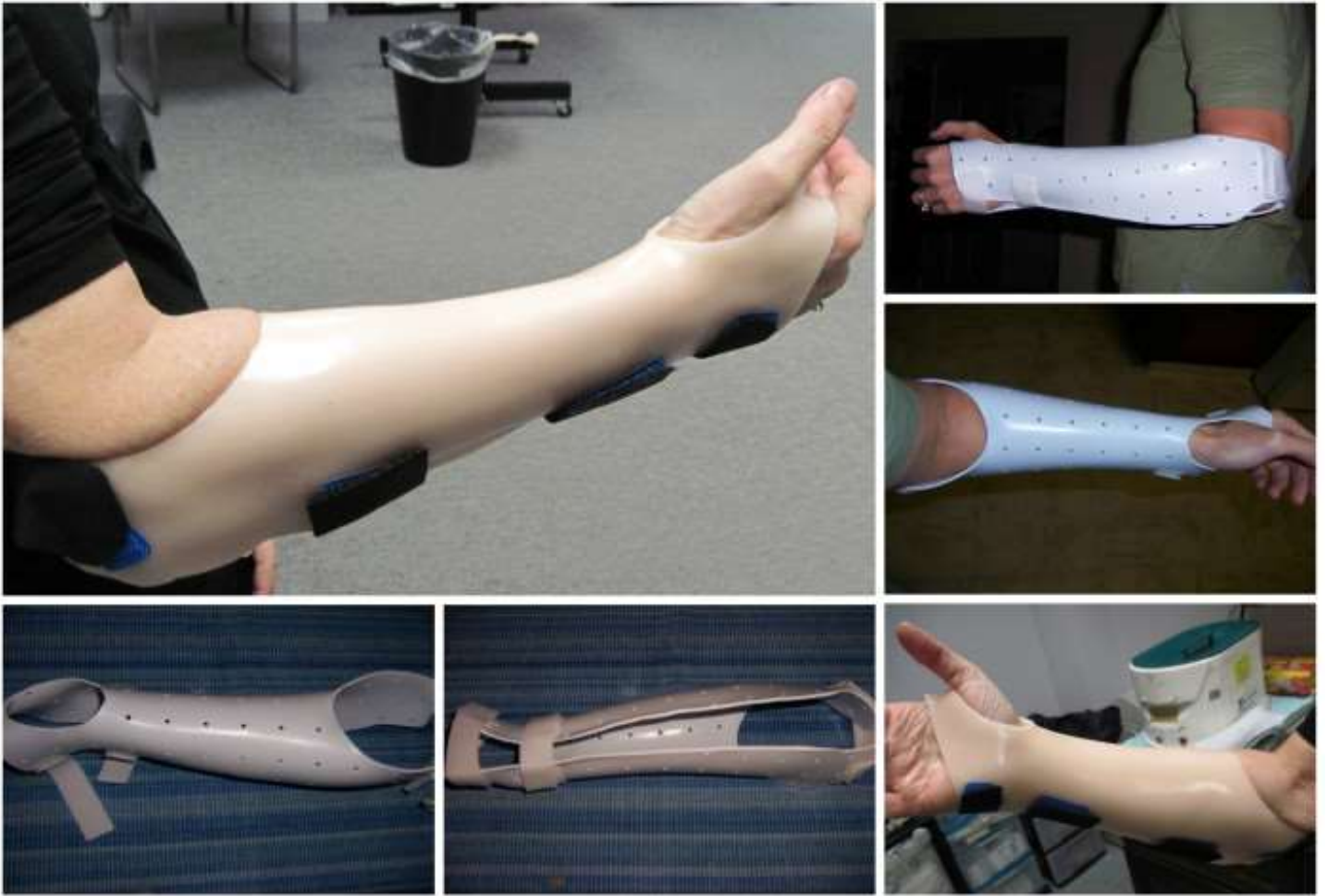

IMAGE 16

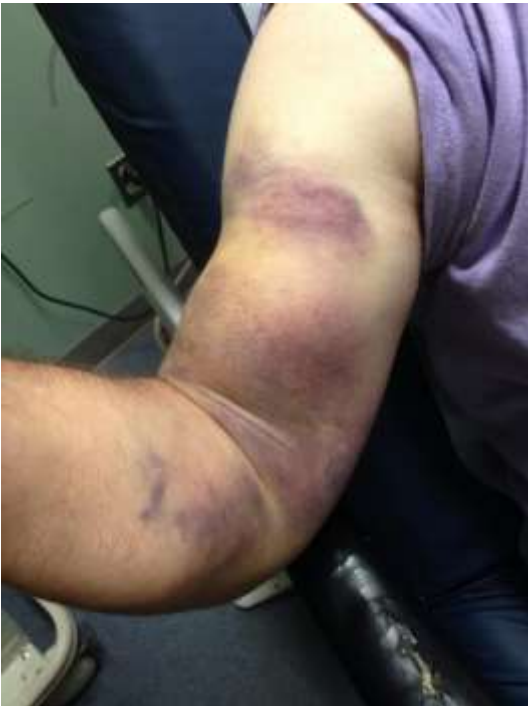

IMAGE 17

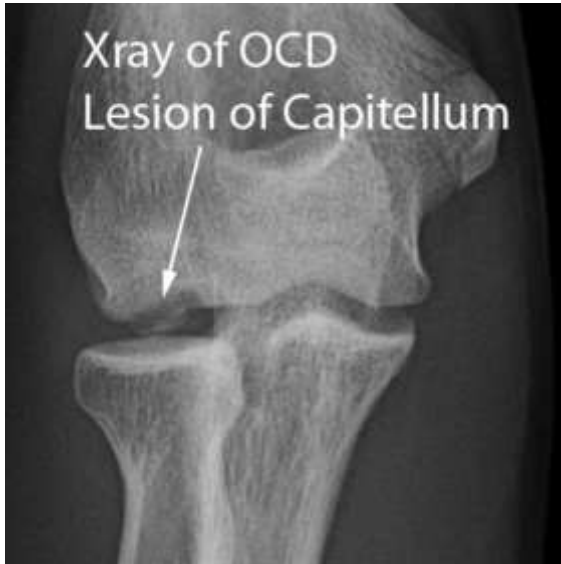


IMAGE 18

LEGO PAIN ASSESSMENT TOOL

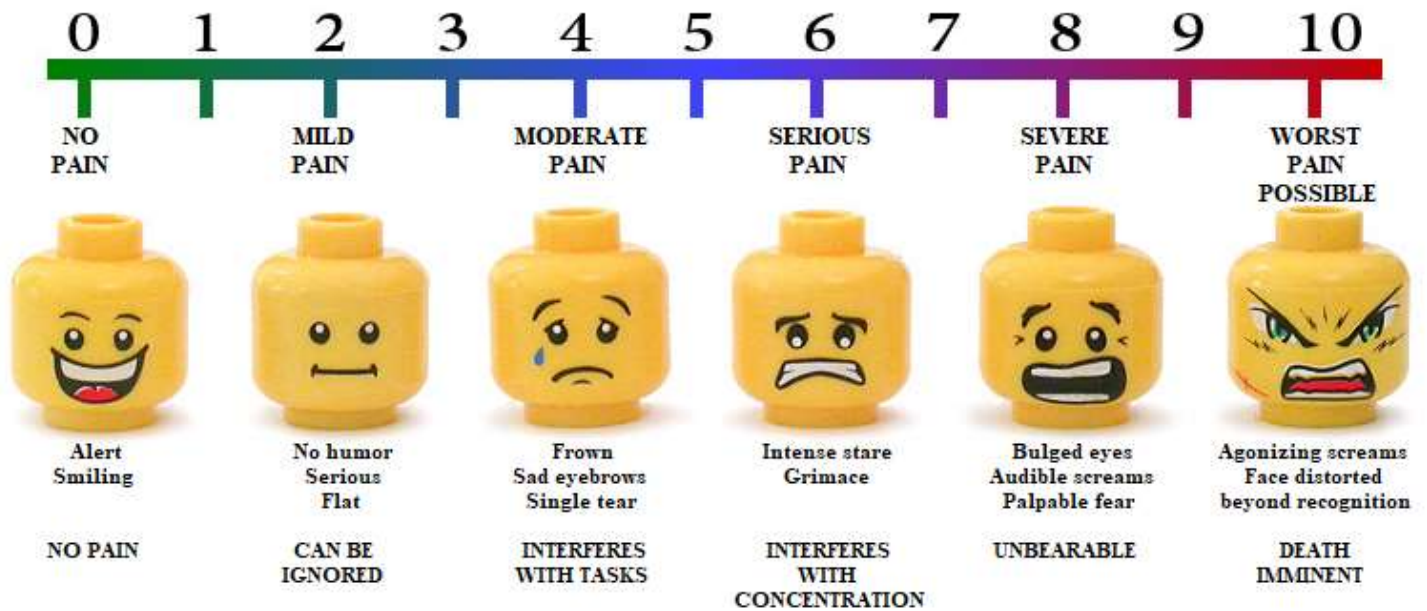
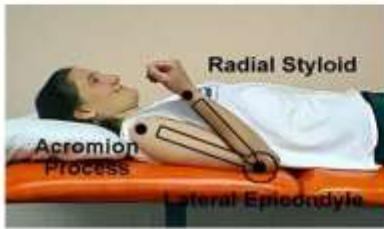

IMAGE 19

Elbow flexion(0~150°)



Test Position

- Subject supine
- Shoulder neutral (arm at side)
- Forearm supinated
- Elbow flexed
- Stabilize arm

Goniometer Alignment

- Axis – lateral epicondyle of humerus
- Stationary arm – aligned with humerus (center of acromion process)
- Moving arm – aligned with radius (styloid process)

IMAGE 20

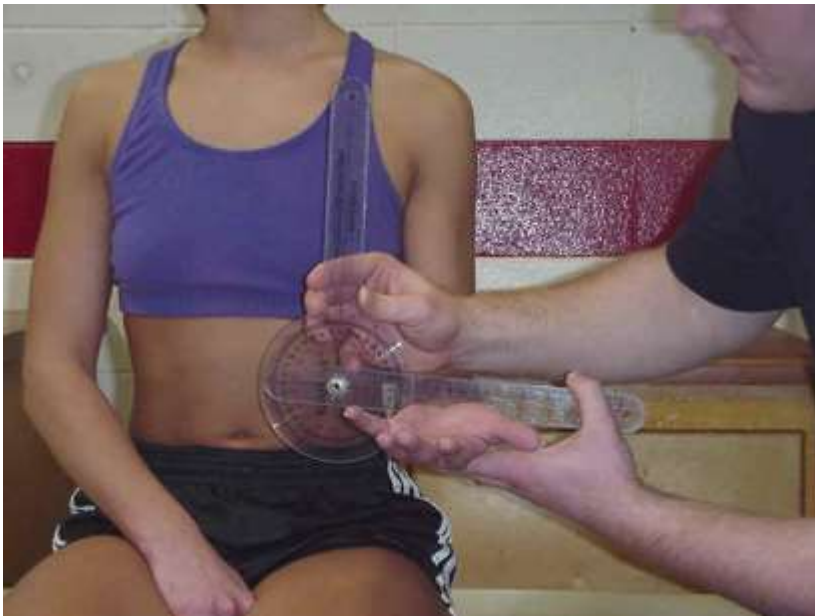

IMAGE 21



IMAGE 22




IMAGE 23




IMAGE 24



IMAGE 25



IMAGE 26



IMAGE 27

